

# IMAGE OF CORRECT PANORAMA

---



Written by overseas business dept in vatech

Value Added Technologies Co., Ltd. Tel: +82-31-377-9104 Fax: +82-31-377-1882

# CONTENTS

---

□	1. Image of correct panorama .....	2
□	2. Method of correct capturing	
	2.1 Caution .....	4
	2.2 Check posture .....	5
	2.3 Checking location of beam .....	7
□	3. Example of fault image caused by incorrect posture	
	3.1 Alignment of beam .....	9
	3.2 Posture .....	11
	3.2 Ghost .....	18
	3.3 Dose or x-ray .....	19
□	Appendix	
	A. Image Layer .....	22
	B. Produce principle and direction of image .....	23
	C. Assortment of fault image	
	C.1 Alignment of patient .....	24
	C.2 Image of ghost .....	26

---

# 1. IMAGE OF CORRECT PANORAMA

---

Explain what condition we should have to make ideal image.

## 1. Image of correct panorama

---

- ① Front teeth should be in the middle of image
- ② Tmj height and vacant space of right and left should be equal
- ③ occlusal plane is smiling

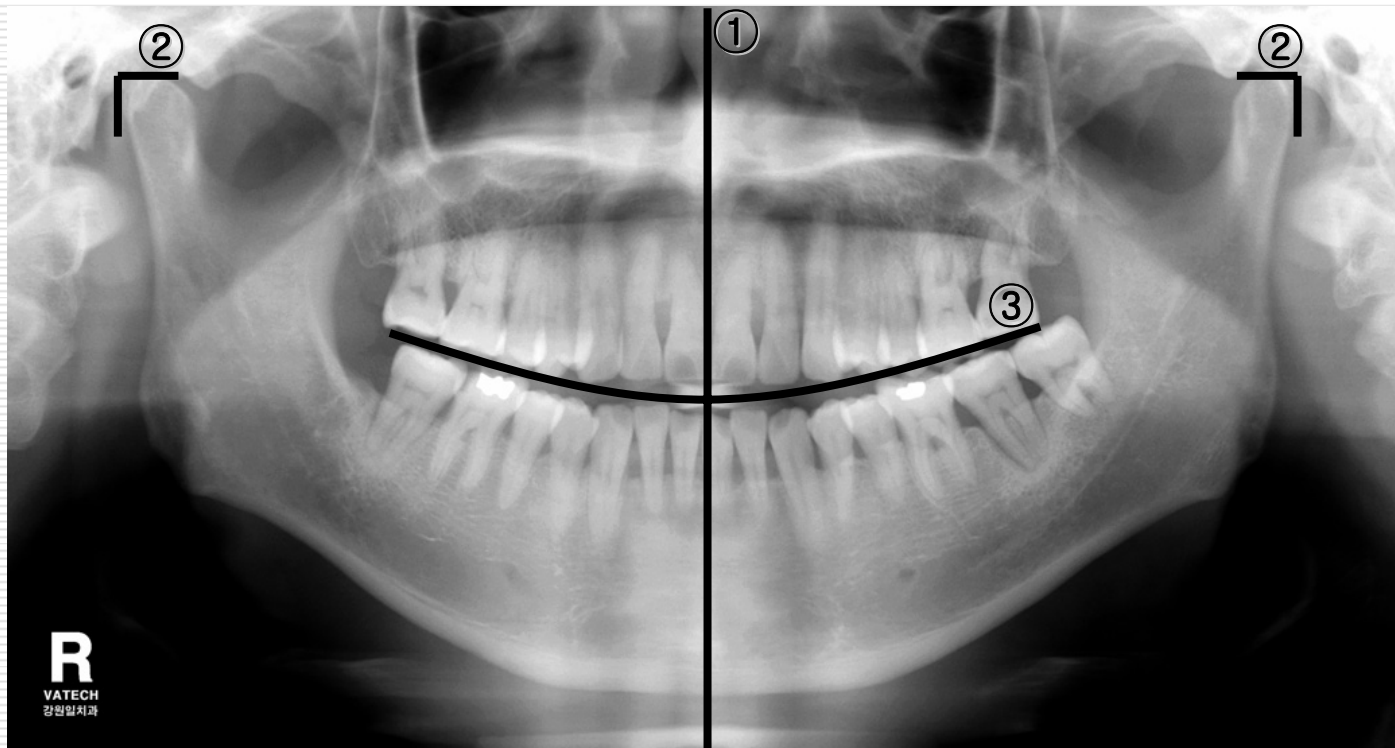


Image of correct panorama

## 2. METHOD OF CORRECT CAPTURING

---

Capture order to capture ideal panorama image

## 2. Method of correct capturing (caution)

---

- ① Remove metal material around neck and head  
(eyeglasses, jewel, denture, bridge, hearing aid etc)



- ② Wear protect clothing (pb apron)

## 2. Method of correct capturing (check posture1)

### ③ Adjust vertical carriage to patient




- ④ Have patient stand straight to the device  
(align legs to the line indicated on the picture)

## 2. Method of correct capturing (check posture 2)

---

⑤ Have patient hold hand bar



⑥ Cover hygiene cover to bite block,  
Have patient bite block home with front teeth

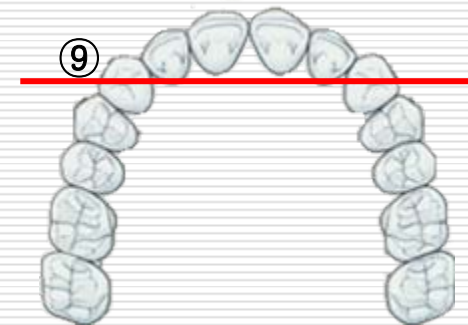
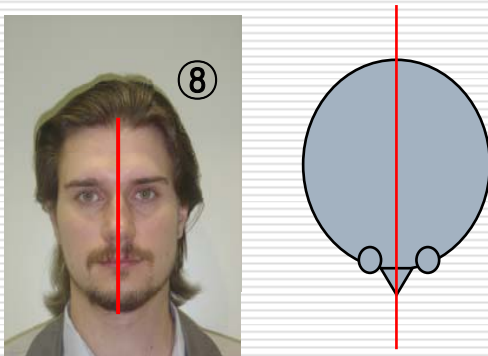


## 2. Method of correct capturing ( check of beam location )

- ⑦ Check frank beam passing  
frankfurt of face



- ⑧ Check sagittal beam passing mid-  
sagittal plane of face



- ⑨ Adjust canine beam to canine of  
patient

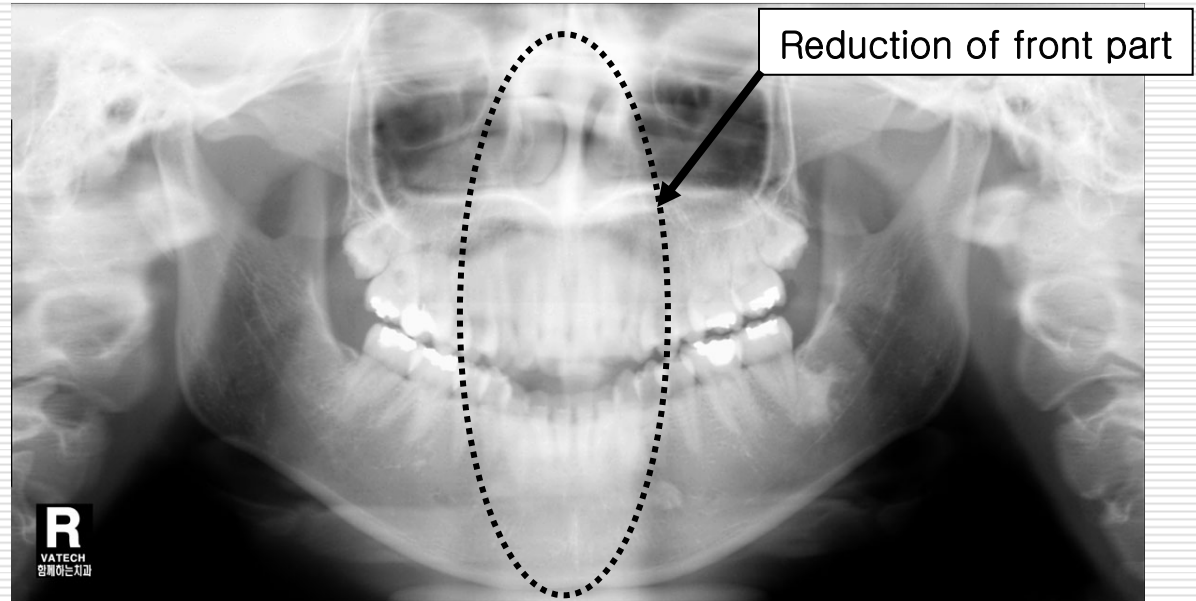
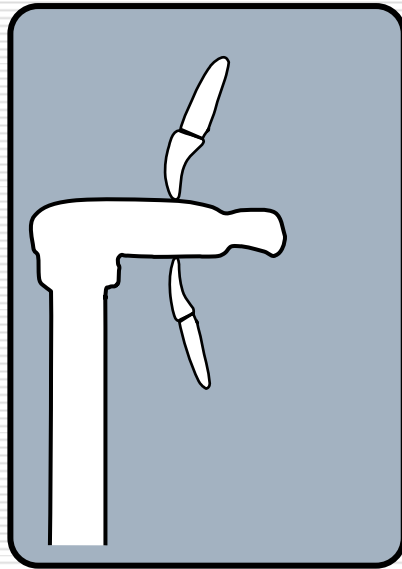
### 3. FAULT IMAGE CAUSED BY INCORRECT POSTURE

---

Introduce fault image caused by incorrect image and explain how to solve it

### 3. Example of fault image caused by incorrect posture (beam alignment1)

- ❑ When patient stand close to front



Situation : ① front teeth part is faint  
② small molar teeth looks folded from time to time

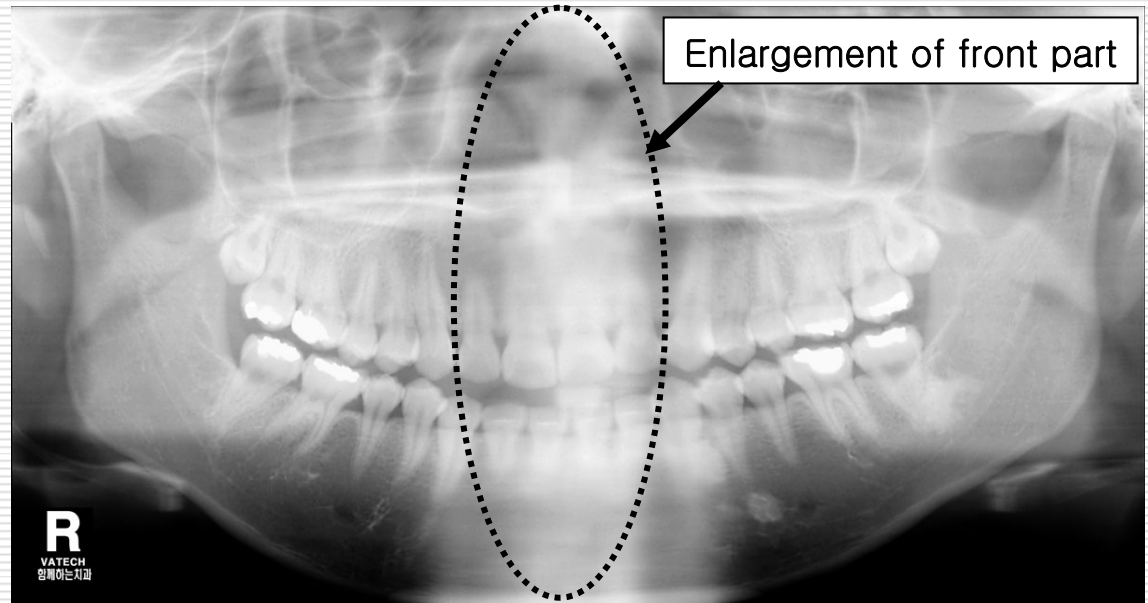
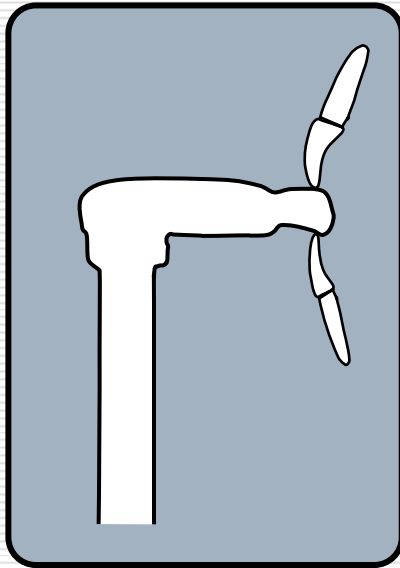
- ❑ Cause : ① when patient bite biteblock deeply, when canine beam isn't aligned correctly

② when patient stand close to front

- ❑ Solution : ① confirm patient bite biteblock exactly  
② align canine beam

### 3. Example of fault image caused by incorrect posture (beam alignment2)

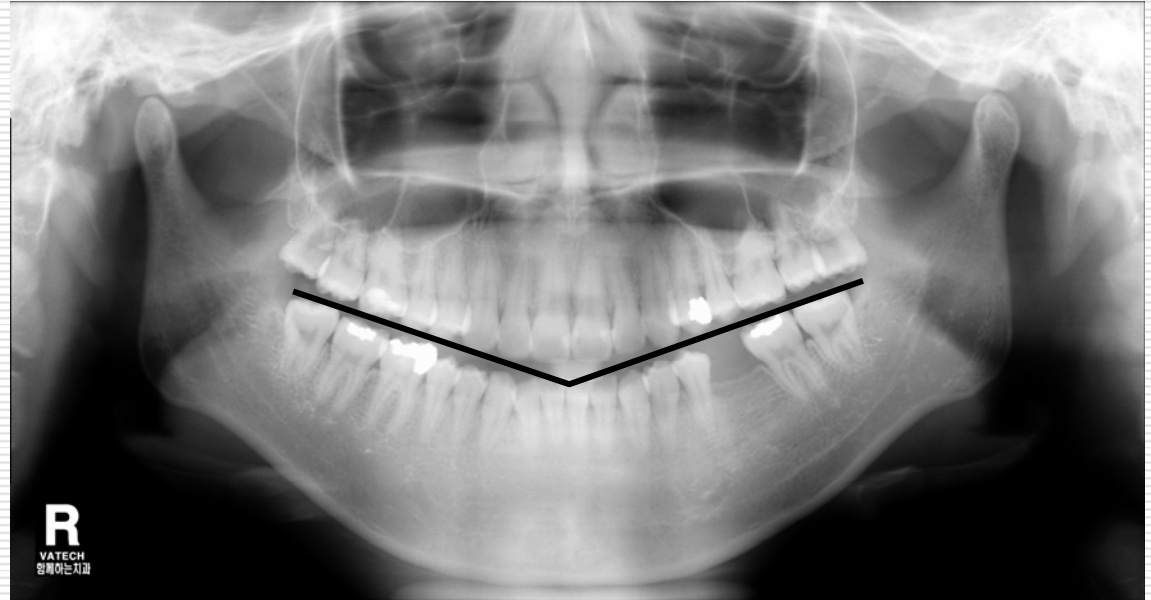

- When patient stand far from device



- Situation : ① front teeth part is faint and wide, jawbone looks dark
- Cause : ① When patient stand far from device
- Solution : ① confirm patient bite biteblock exactly  
② align canine beam

### 3. Example of fault image caused by incorrect posture (posture 1)

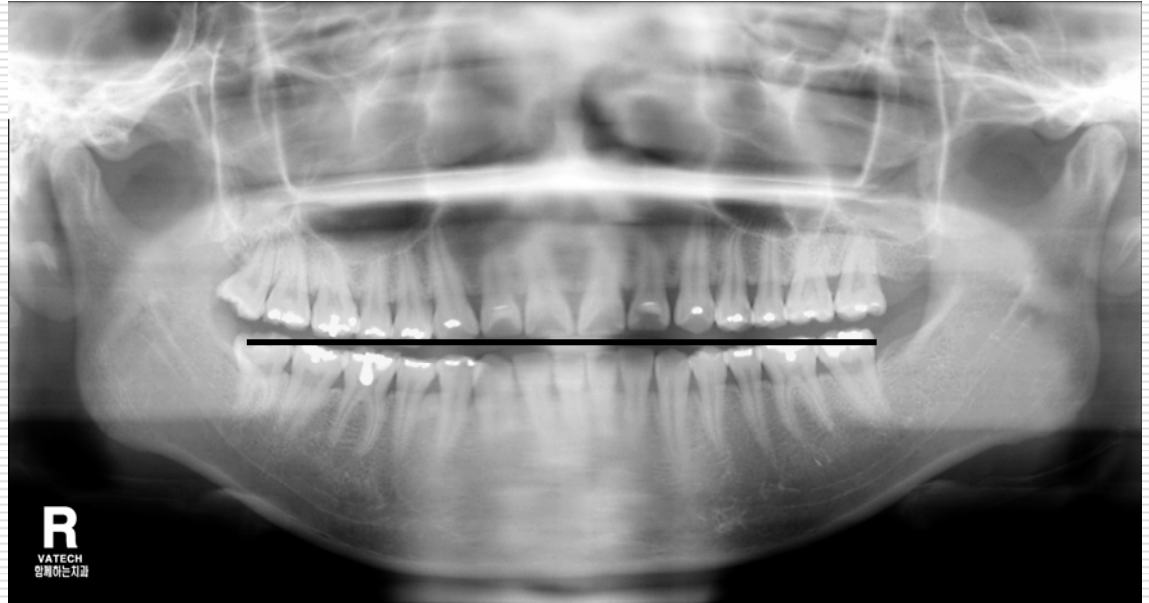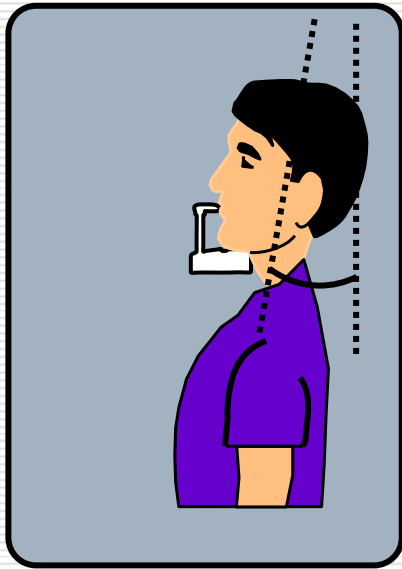
- When patient too keeps head down



- Situation : ① root of front teeth part is faint, small molar part looks folded
- Cause : ① When patient too keeps head down
- Solution : ① control vertical carriage up  
② if this situation keeps same, dentition of the patient isn't normal

### 3. Example of fault image caused by incorrect posture (posture 2)

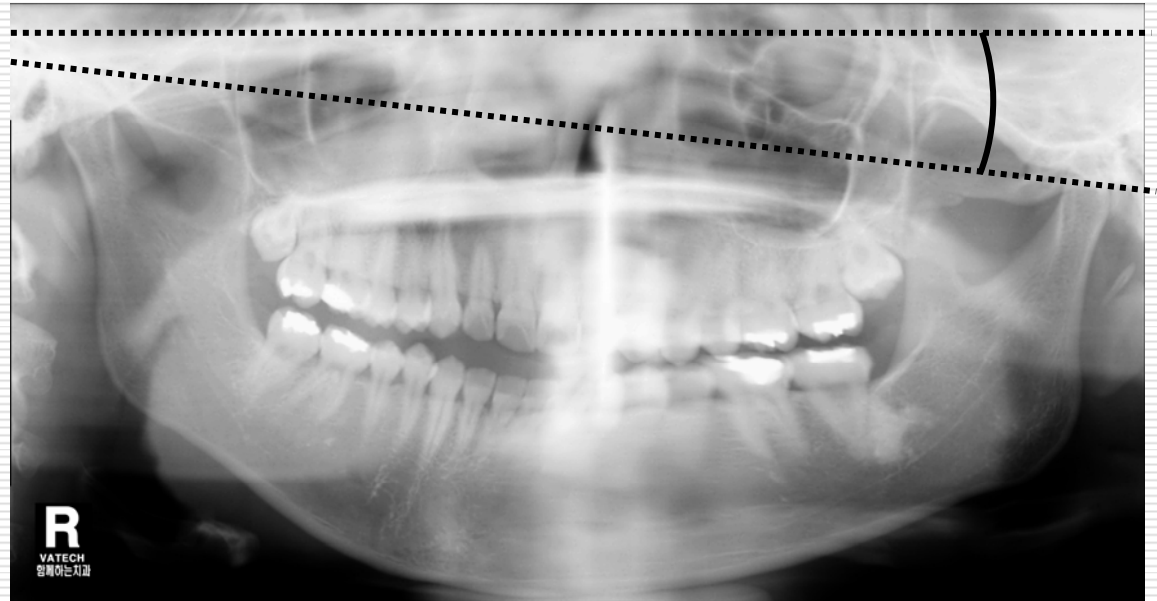
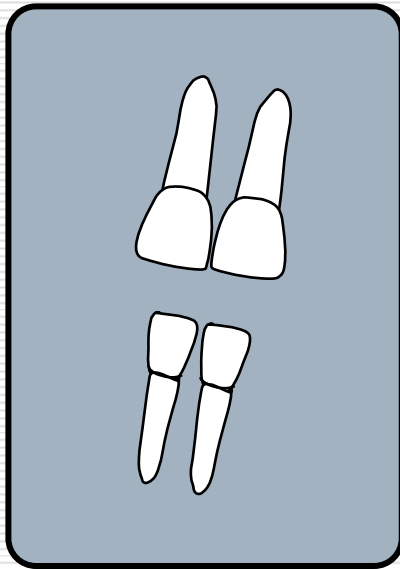
- When patient too keeps head up



- Situation : ① root of front teeth part is faint
- Cause : ① When patient too keeps heads up
- Solution : ① control vertical carriage down  
② when under jaw needs to be clear to see we sometimes capture like above

### 3. Example of fault image caused by incorrect posture (posture 3)

- When patient tilts head

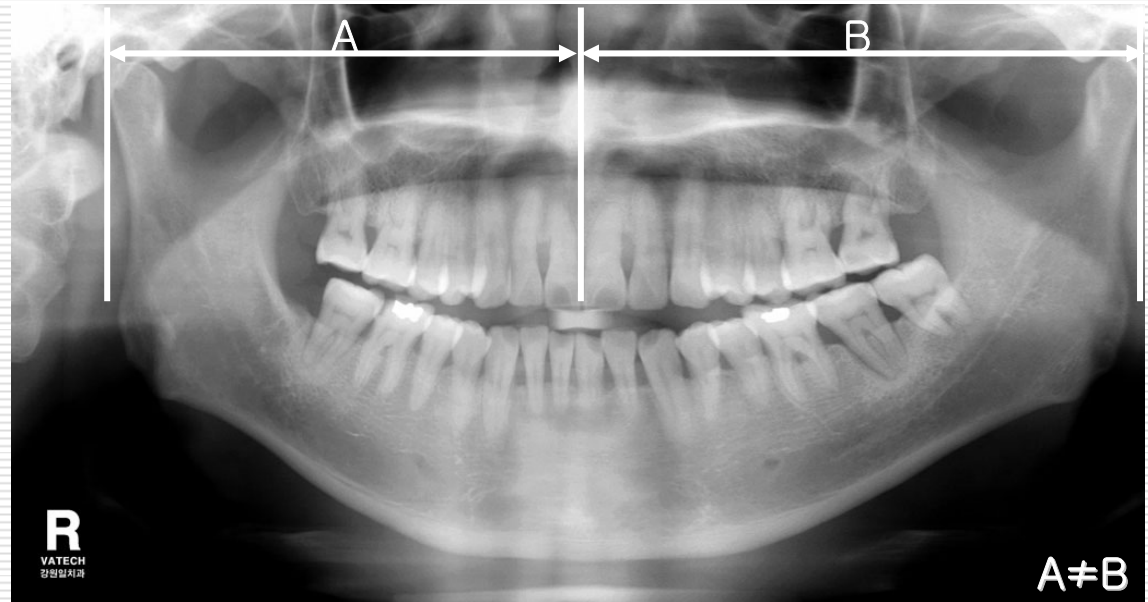
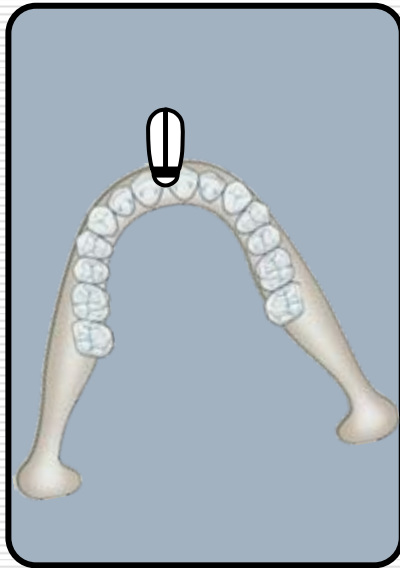


- Situation : ① image looks inclined, enlargement ratio of right and left looks different and faint
- Cause : ① When patient tilts head
- Solution : ① adjust sagittal beam to Mid-Sagittal plane of patient



### 3. Example of fault image caused by incorrect posture (posture 4)

#### □ When patient turns head

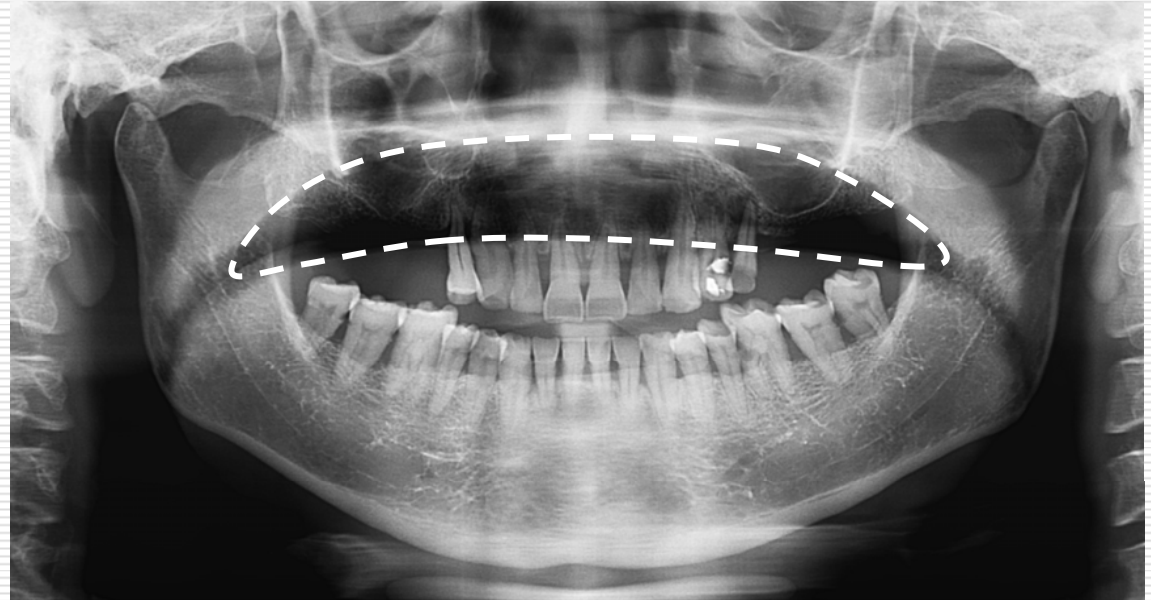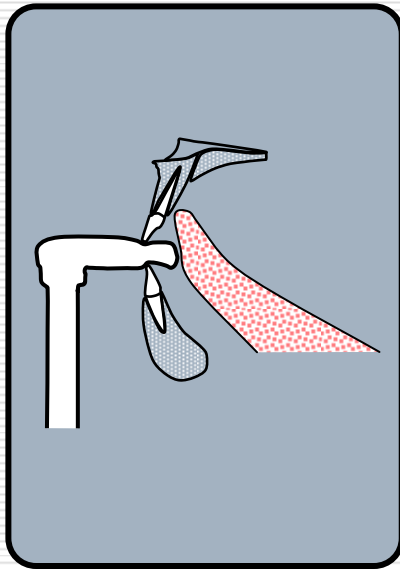


- Situation : ① enlargement ratio of right and left looks different, a part of chin looks wide
- Cause : ① When patient turns head
- Solution : ① adjust sagittal beam to Mid-Sagittal plane of patient  
② confirm alignment behind patient



### 3. Example of fault image caused by incorrect posture (posture 5)

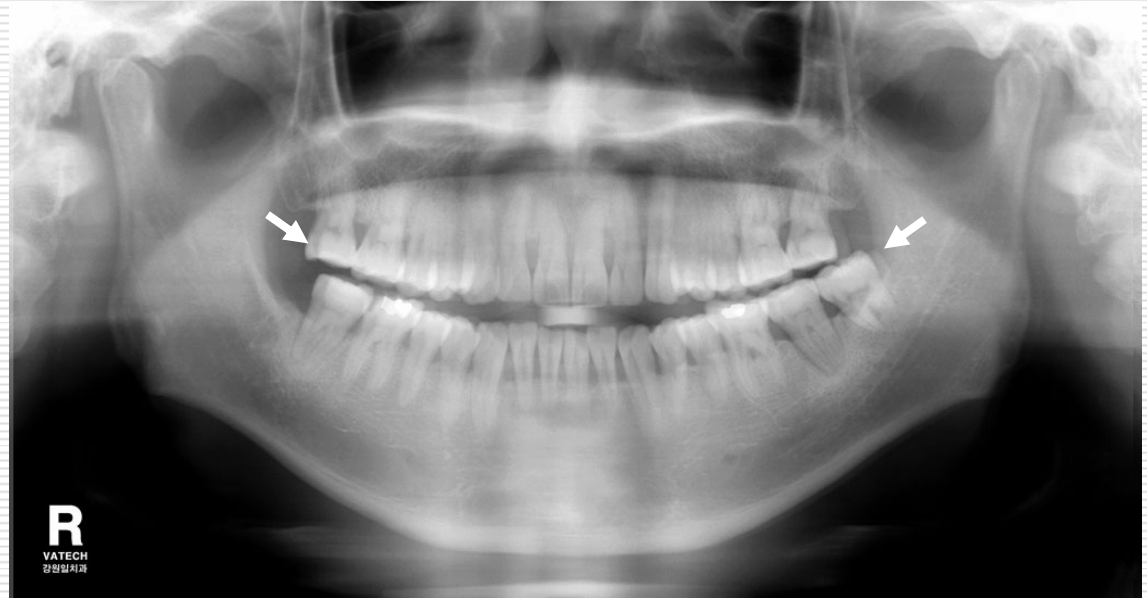
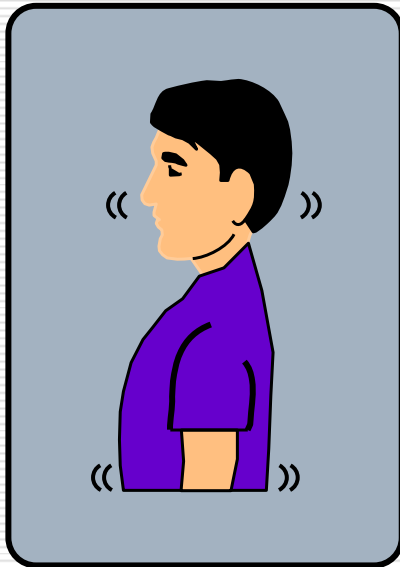
- ❑ When upper jaw looks dark



- ❑ Situation : ① upper jaw looks dark
- ❑ Cause : ① when patient does not keep tongue to palate
- ❑ Solution : ① while capturing, ask patient to keep tongue to palate

### 3. Example of fault image caused by incorrect posture (posture 6)

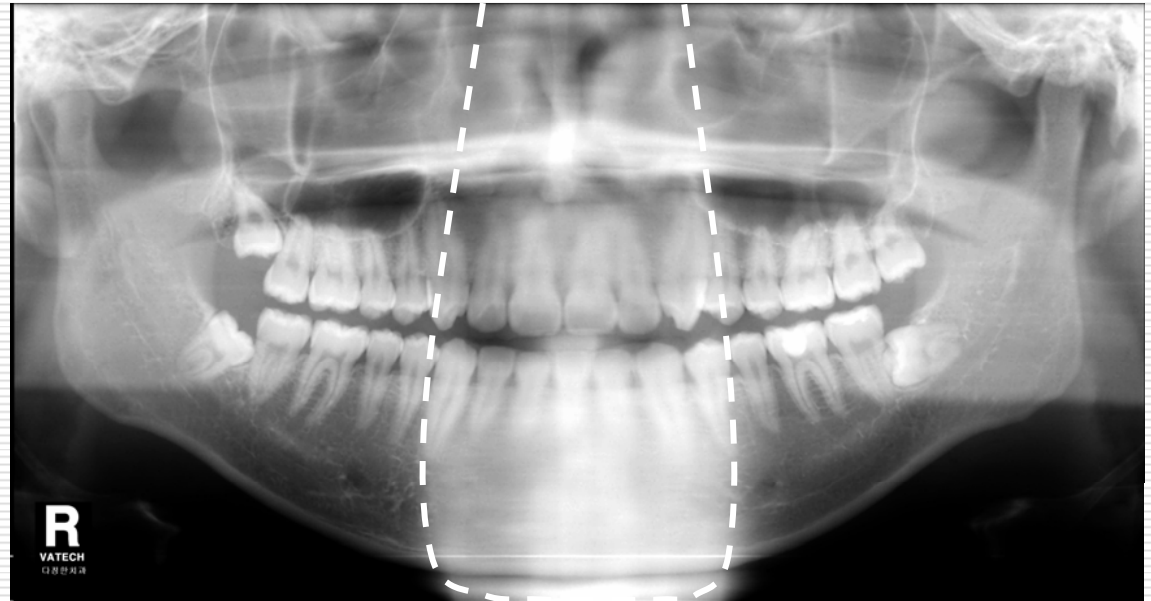

#### □ When patient moves



- Situation : ① whole image is faint , clearness of line is not good  
② there is shaking part in the image
- Cause : ① When patient moves
- Solution : ① comfort patient who is not familiar with device  
② ask patient not to move during capturing

### 3. Example of fault image caused by incorrect posture (posture 7)

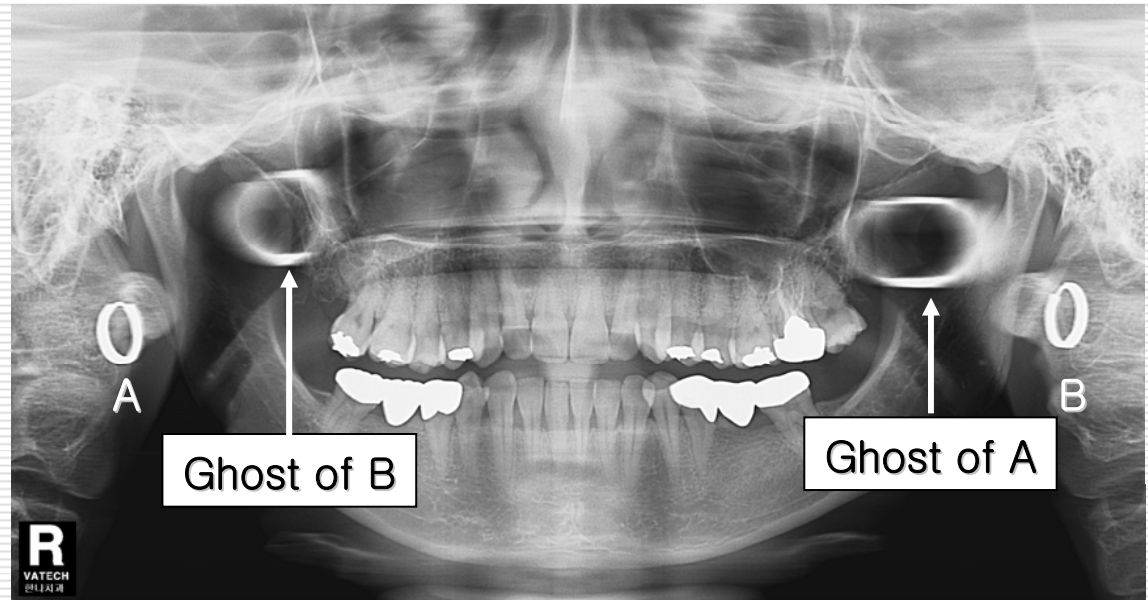

#### □ When posture is bent



- Situation : ① happens ghost image of pyramid shape in the middle of image
- Cause : ① when posture is bent
- Solution : ① keep patient's spine straight  
② keep shoulder down so that end of chin doesn't reach nape  
③ adjust vertical carriage up

### 3. Example of fault image caused by incorrect posture (ghost 1)

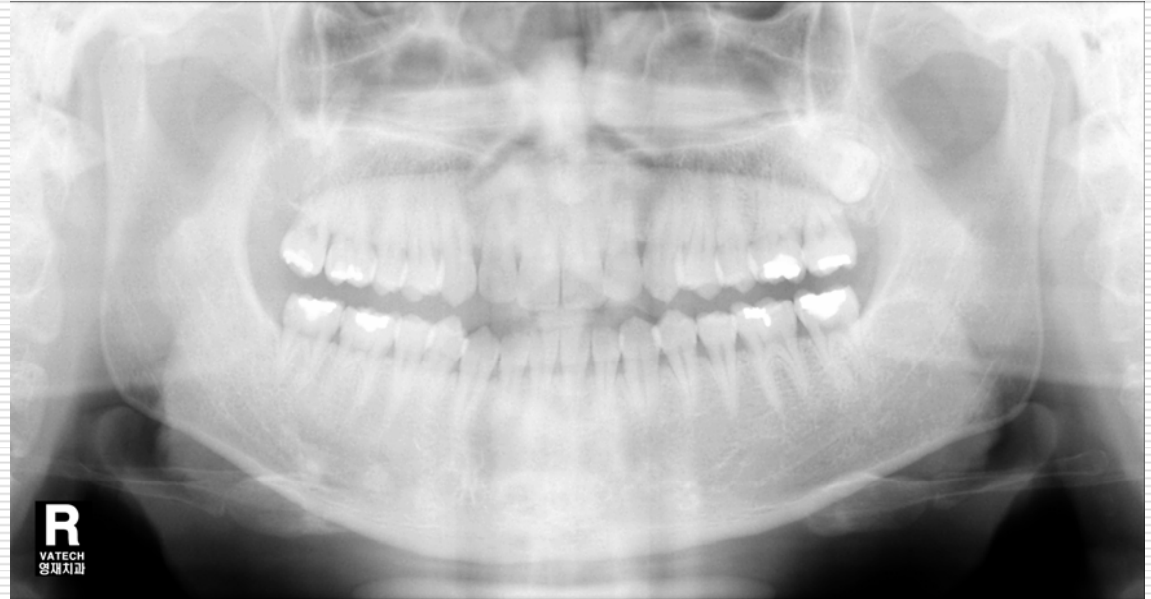
- When patient wears metal material



- Situation : ① happens ghost image caused by metal material
- Cause : ① When patient wears metal material
- Solution : ① capture image after removing eyeglasses, jewel, denture, bridge, hearing aid etc

### 3. Example of fault image caused by incorrect posture ( dosage 1)

- When the image is too bright

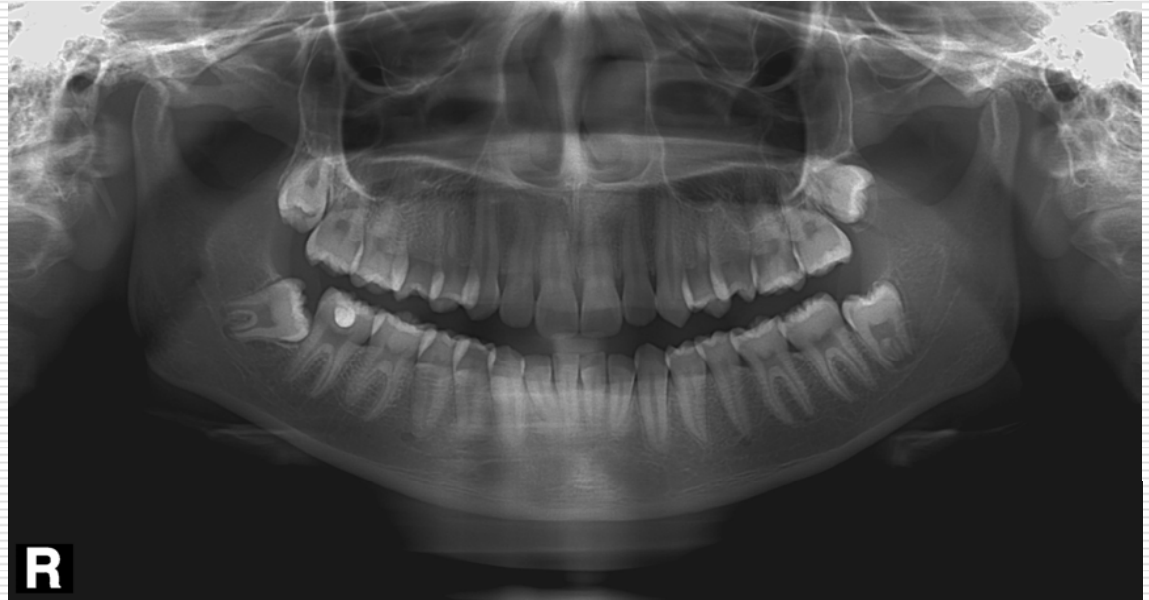


- Situation : ① image is too bright
- Cause : ① when x-ray(power) is weak
- Solution : ① set up kVp and mA high to give patient proper dosage

### 3. Example of fault image caused by incorrect posture ( dosage 2)

---

- ❑ When image is too dark



- ❑ Situation : ① image is too dark
- ❑ Cause : ①when x-ray(power) is strong
- ❑ Solution : ①set up kvp and ma down to give patient proper dosage

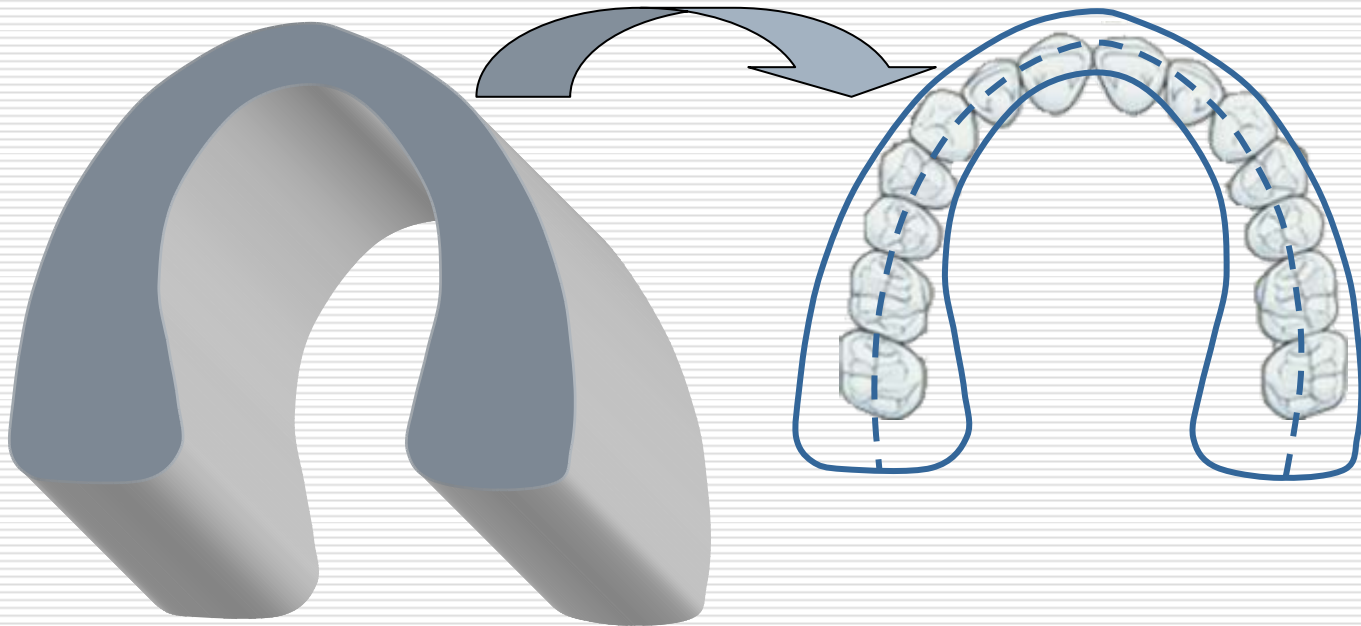
# Appendix

---



## Appendix A. Image Layer

Image Layer : space united with dentition between x-ray tube and sensor

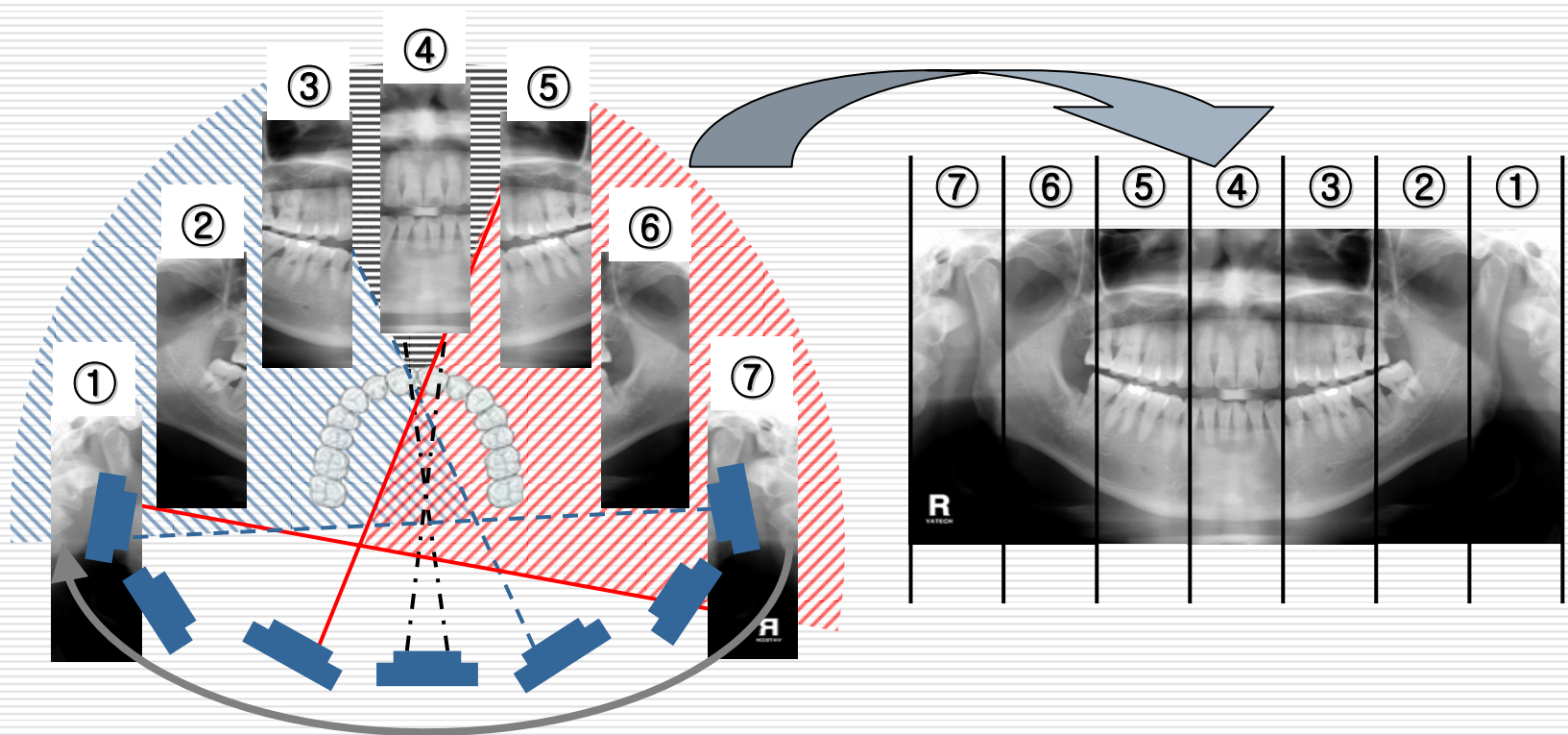


- \* when dentition is located on image layer, the quality of image is good  
In case of capturing front teeth, the image layer so small that we need to set patient alignment with caution



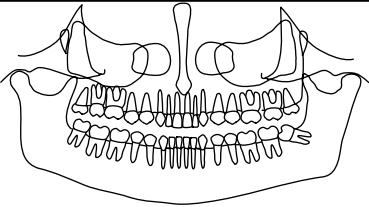
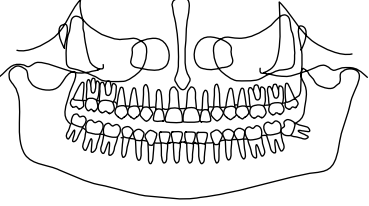
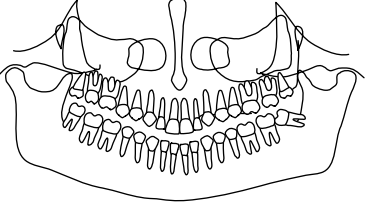
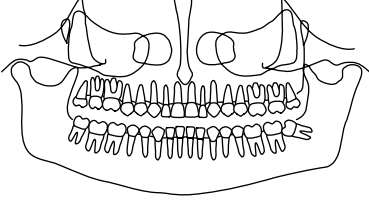
## Appendix B. Produce principle and direction of image

- **Principle** : While x-ray tube is circling around patient, x-ray beam penetrate jaw chin and produce consecutive images that will be one image
- **Direction** : Because we look image like we see patient, right part of patient is expressed in the left of image



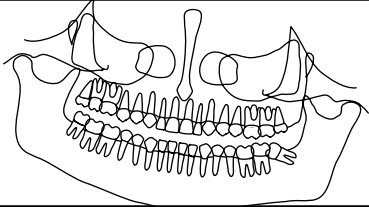
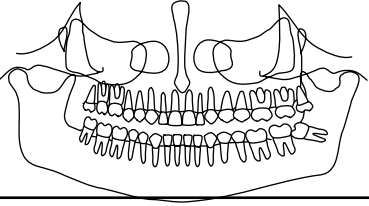
## Appendix C. Assortment of fault image

### Alignment of patient 1

Situation		Cause	Solution / Page related	
	<ul style="list-style-type: none"> <li>front teeth part is faint and small</li> <li>small molar teeth looks folded from time to time</li> </ul>	<ul style="list-style-type: none"> <li>when patient bite biteblock deeply</li> <li>When front teeth is located in front of image layer</li> </ul>	<ul style="list-style-type: none"> <li>confirm patient bite bite block exactly</li> <li>align canine beam</li> </ul>	9
	<ul style="list-style-type: none"> <li>front teeth part is faint and wide, jawbone looks dark</li> </ul>	<ul style="list-style-type: none"> <li>When patient stand far from device</li> <li>When front teeth is located behind image layer</li> </ul>	<ul style="list-style-type: none"> <li>confirm patient bite bite block exactly</li> <li>align canine beam</li> </ul>	10
	<ul style="list-style-type: none"> <li>root of front teeth part is faint, small molar part looks folded</li> <li>Image is too smiling</li> </ul>	<ul style="list-style-type: none"> <li>When patient too keeps head down</li> <li>When front teeth is out of image layer</li> </ul>	<ul style="list-style-type: none"> <li>control vertical carriage up</li> <li>if this situation keeps same, dentition of the patient isn't normal</li> </ul>	11
	<ul style="list-style-type: none"> <li>root of front teeth part is faint</li> <li>Image is not smiling</li> </ul>	<ul style="list-style-type: none"> <li>When patient too keeps heads up</li> </ul>	<ul style="list-style-type: none"> <li>control vertical carriage down</li> <li>when under jaw needs to be clear to see we sometimes capture like picture</li> </ul>	12

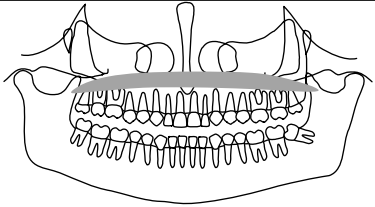
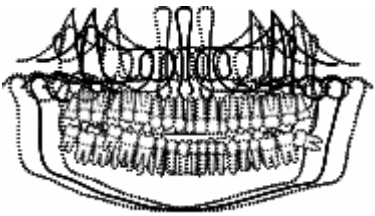
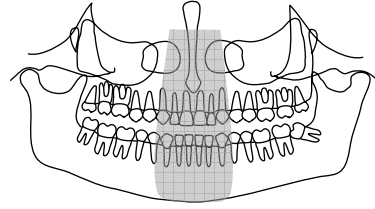
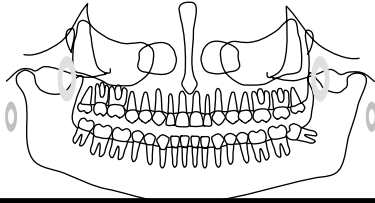
## Appendix C. (Assortment of fault image)

### □ Alignment of patient 2

Situation		Cause	Solution / Page related	
	<input type="checkbox"/> image looks inclined, enlargement ratio of right and left looks different and faint	<input type="checkbox"/> When patient tilts head <input type="checkbox"/> Root of lower front teeth is out of image layer	<input type="checkbox"/> adjust sagittal beam to Mid-Sagittal plane of patient	13
	<input type="checkbox"/> enlargement ratio of right and left looks different	<input type="checkbox"/> When patient turns head	<input type="checkbox"/> adjust sagittal beam to Mid-Sagittal plane of patient	14

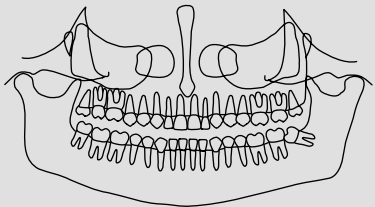
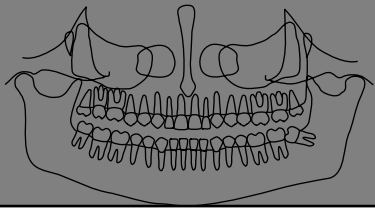
## Appendix C. (Assortment of fault image)

### ❑ Image of ghost 1

Situation		Cause	Solution / Page related	
	<ul style="list-style-type: none"> <li>❑ upper jaw looks dark</li> <li>❑ Image between upper jaw and nose looks dark</li> </ul>	<ul style="list-style-type: none"> <li>❑ when patient dose not keep tongue to palatine</li> </ul>	<ul style="list-style-type: none"> <li>❑ while capturing, ask patient to keep tongue to palatine</li> </ul>	15
	<ul style="list-style-type: none"> <li>❑ whole image is faint , clearness of line is not good</li> <li>❑ there is shaking part in the image</li> </ul>	<ul style="list-style-type: none"> <li>❑ when patient moves</li> </ul>	<ul style="list-style-type: none"> <li>❑ comport patient who is not familiar with device</li> <li>❑ ask patient not to move during capturing</li> </ul>	16
	<ul style="list-style-type: none"> <li>❑ happens ghost image of pyramid shape in the middle of image</li> </ul>	<ul style="list-style-type: none"> <li>❑ when posture is bented</li> </ul>	<ul style="list-style-type: none"> <li>❑ keep patient's spine straight</li> <li>❑ keep shoulder down so that end of chin dosen't reach nape</li> <li>❑ adjust vertical carriage up</li> </ul>	17
	<ul style="list-style-type: none"> <li>❑ happens ghost image caused by metal material</li> </ul>	<ul style="list-style-type: none"> <li>❑ when patient wears metal material</li> </ul>	<ul style="list-style-type: none"> <li>❑ capture image after removing eyeglasses, jewel, denture, bridge, hearing aid etc</li> </ul>	18

## Appendix C. Assortment of fault image

### ❑ Image of ghost 2

Situation		Cause	Solution / Page related	
	❑ image is too bright	❑ when x-ray(power) is weak ❑ capture adult with child mode ❑ neck is not straight	❑ set up kVp and mA high to give patient proper dosage ❑ Keep neck straight	19
	❑ image is too dark	❑ when x-ray(power) is strong	❑ set up kVp and mA down to give patient proper dosage	20